

Poisonous plants in New Zealand: a review of those that are most commonly enquired about to the National Poisons Centre

Robin J Slaughter, D Michael G Beasley, Bruce S Lambie, Gerard T Wilkins, Leo J Schep

Abstract

Introduction New Zealand has a number of plants, both native and introduced, contact with which can lead to poisoning. The New Zealand National Poisons Centre (NZNPC) frequently receives enquiries regarding exposures to poisonous plants. Poisonous plants can cause harm following inadvertent ingestion, via skin contact, eye exposures or inhalation of sawdust or smoked plant matter.

Aim The purpose of this article is to determine the 15 most common poisonous plant enquiries to the NZNPC and provide a review of current literature, discussing the symptoms that might arise upon exposure to these poisonous plants and the recommended medical management of such poisonings.

Methods Call data from the NZNPC telephone collection databases regarding human plant exposures between 2003 and 2010 were analysed retrospectively. The most common plants causing human poisoning were selected as the basis for this review. An extensive literature review was also performed by systematically searching OVID MEDLINE, ISI Web of Science, Scopus and Google Scholar. Further information was obtained from book chapters, relevant news reports and web material.

Results For the years 2003–2010 inclusive, a total of 256,969 enquiries were received by the NZNPC. Of these enquiries, 11,049 involved exposures to plants and fungi. The most common poisonous plant enquiries, in decreasing order of frequency, were: black nightshade (*Solanum nigrum*), arum lily (*Zantedeschia aethiopica*), kowhai (*Sophora* spp.), euphorbia (*Euphorbia* spp.), peace lily (*Spathiphyllum* spp.), agapanthus (*Agapanthus* spp.), stinking iris (*Iris foetidissima*), rhubarb (*Rheum rhabarbarum*), taro (*Colocasia esculentum*), oleander (*Nerium oleander*), daffodil (*Narcissus* spp.), hemlock (*Conium maculatum*), karaka (*Corynocarpus laevigatus*), foxglove (*Digitalis purpurea*) and ongaonga/New Zealand tree nettle (*Urtica ferox*). The combined total of enquiries for these 15 species was 2754 calls (representing approximately 25% of all enquiries regarding plant exposures). The signs and symptoms resulting from poisoning from these plants are discussed. Medical treatment recommendations are made.

Conclusion Poisoning following ingestion or other forms of exposures to plants in New Zealand is relatively common, particularly among children. However, serious adverse reactions are comparatively rare. Accurate plant identification and details on the type of exposure can be important in assessing the likely risks. Effective medical management of these poisonings can be achieved by following the principles outlined in this review.

New Zealand is host to a number of poisonous plants, both native and introduced, contact with which can lead to poisoning. Typically poisonous plants cause harm following inadvertent ingestion or via contact with the skin, but eye exposures to plant material or inhalation of sawdust or smoked plant matter are also exposure routes which may lead to poisoning.

Young children most commonly ingest plant material; this is typically due to their having a natural curiosity about their surroundings and their tendency for oral exploration,¹ whereas adults tend to more commonly come into contact with poisonous plants via skin or eye contact following gardening or yard work. Occasionally there may be intentional ingestions, or poisonous species may be mistaken for an edible plant and ingested as food, or made into drinks such as infusions or teas.

Children are unlikely to develop significant effects following small exploratory ingestions of the majority of plants. However, there are some plants, when ingested in sufficient quantity, which are capable of causing severe poisoning in both children and adults.

The New Zealand National Poisons Centre (NZNPC) frequently receives enquiries regarding exposures to poisonous plants. In children, exposures are typically reported soon after ingestion when parents notice plant matter in the child's mouth or notice the child playing with parts of the plant. Conversely adults exposed to a poisonous plant may only contact the Poisons Centre when they become symptomatic.

In this review we examine the poisonous plants about which the NZNPC most commonly receives enquiries and include their botanical descriptions, toxins present, mechanisms of toxicity and toxic effects and also provide comprehensive poisoning treatment protocols.

Methods

The NZNPC is the sole Poison Information Centre for New Zealand; covering a population of approximately 4.4 million people, it serves a mixed population of urban and rural areas. The NZNPC uses an in-house telephone collection system; it is built on Firebird™ v2.0.3 software which is developed by the Firebird Project. This system logs information pertaining to all enquires received by the NZNPC. Call data from the telephone collection database regarding human plant exposures were analysed retrospectively for the years 2003-2010 inclusively. Excluded were enquires regarding exposure to known non-poisonous plants, mushroom/fungi exposures, unidentified plants, animal poisonings and requests for general information in the absence of an actual exposure.

The 15 most commonly enquired about plants over the 8-year period were selected as the basis for this review. Some of these, however, possess similar toxins, mechanisms of action and/or clinical effects, and such plants were considered as a single entity. For example oleander and foxglove both contain toxic cardiac glycosides and have a comparable toxidrome.

In compiling the review article, an extensive literature review was performed by searching Ovid MEDLINE, ISI Web of Science, Scopus and Google Scholar. Initial searching of these databases was done using specific species and common names of the plants, along with the keywords 'poisoning', 'poison', 'toxicity', 'ingestion', 'adverse effects', 'overdose', 'intoxication' and 'toxin' to identify relevant articles. Bibliographies of identified articles were screened for additional relevant studies including non-indexed reports. In addition, non-peer-reviewed sources were also included; further information was obtained from book chapters, relevant news reports and applicable internet resources.

Results

For the years 2003–2010 inclusive, a total of 256,969 enquiries were received by the NZNPC, of which 171,130 were related to acute human exposure. Of these exposure enquiries, 11,049 (6.5%) involved plants and fungi.

The most common poisonous plant enquiries involved, in decreasing order of frequency, were black nightshade (*Solanum nigrum*), arum lily (*Zantedeschia aethiopica*), kowhai (*Sophora* spp.), euphorbia (*Euphorbia* spp.), peace lily (*Spathiphyllum* spp.), agapanthus (*Agapanthus* spp.), stinking iris (*Iris foetidissima*), rhubarb (*Rheum rhabarbarum*), taro (*Colocasia esculentum*), daffodil (*Narcissus* spp.), oleander (*Nerium oleander*), hemlock (*Conium maculatum*), karaka (*Corynocarpus laevigatus*), ongaonga/New Zealand tree nettle (*Urtica ferox*), and foxglove (*Digitalis purpurea*).

The combined total number of calls for these 15 species was 2754 (representing approximately 25% of all enquiries regarding plant exposures). Children (less than 12 years of age) were involved in 2210 (80%) of these calls while adults were involved in 544 (20%). The number of enquiries received for each of the 15 species over the 8 year period along with the number regarding children or adults are presented in Table 1.

Table 2 shows the number of exposures by different routes for each of the 15 species. The route of exposure was classified as either ingestion, eye contact, skin contact or inhalation (e.g. exposure following the inhalation of sawdust or smoked plant matter).

Table 1. Total enquiries received and numbers of child and adult enquiries for each of the 15 plants from 2003–2010

Common name	Species name	Number of calls	Children	Adults
Black Nightshade	<i>Solanum nigrum</i>	834	749 (90%)	85 (10%)
Arum Lily	<i>Zantedeschia aethiopica</i>	556	520 (93.5%)	36 (6.5%)
Kowhai	<i>Sophora</i> spp.	155	137 (88%)	18 (12%)
Euphorbia	<i>Euphorbia</i> spp.	149	36 (24%)	113 (76%)
Peace Lily	<i>Spathiphyllum</i> spp.	144	143 (99%)	1 (1%)
Agapanthus	<i>Agapanthus</i> spp.	136	108 (79%)	28 (21%)
Stinking Iris	<i>Iris foetidissima</i>	128	123 (96%)	5 (4%)
Rhubarb	<i>Rheum rhabarbarum</i>	121	92 (76%)	29 (24%)
Taro	<i>Colocasia esculentum</i>	95	53 (56%)	42 (44%)
Daffodil	<i>Narcissus</i> spp.	84	56 (67%)	28 (33%)
Oleander	<i>Nerium oleander</i>	81	43 (53%)	38 (47%)
Hemlock	<i>Conium maculatum</i>	77	39 (51%)	38 (49%)
Karaka	<i>Corynocarpus laevigatus</i>	69	61 (88%)	8 (12%)
Ongaonga	<i>Urtica ferox</i>	64	5 (8%)	59 (92%)
Foxglove	<i>Digitalis purpurea</i>	61	45 (74%)	16 (26%)
Total		2754	2210 (80%)	544 (20%)

Table 2. Total enquiries received and route of exposure for each of the 15 plants from 2003-2010

Common name	Species name	Number of calls	Route of exposure			
			Ingestion	Skin	Eye	Inhalation
Black Nightshade	<i>Solanum nigrum</i>	834	778	35	19	2
Arum Lily	<i>Zantedeschia aethiopica</i>	556	525	26	5	–
Kowhai	<i>Sophora</i> spp.	155	152	–	–	3
Euphorbia	<i>Euphorbia</i> spp.	149	31	14	104	–
Peace Lily	<i>Spathiphyllum</i> spp.	144	142	2	–	–
Agapanthus	<i>Agapanthus</i> spp.	136	102	25	7	2
Stinking Iris	<i>Iris foetidissima</i>	128	127	1	–	–
Rhubarb	<i>Rheum rhabarbarum</i>	121	120	1	–	–
Taro	<i>Colocasia esculentum</i>	95	86	8	1	–
Daffodil	<i>Narcissus</i> spp.	84	82	2	–	–
Oleander	<i>Nerium oleander</i>	81	46	23	6	6
Hemlock	<i>Conium maculatum</i>	77	52	22	1	2
Karaka	<i>Corynocarpus laevigatus</i>	69	69	–	–	–
Ongaonga	<i>Urtica ferox</i>	64	1	60	3	–
Foxglove	<i>Digitalis purpurea</i>	61	45	10	5	1
Total		2754	2358	229	151	16

Solanine-containing plants

- **Black Nightshade (*Solanum nigrum*)**

Description—Black nightshade (*Solanum nigrum*) is a common weed distributed widely throughout New Zealand.² The berries are small and round, up to 10 mm in diameter. The fruits are green when unripe, but ripen to a dull black (Figure 1). It has green leaves up to 10 cm long and small white star-shaped flowers with bright yellow anthers² (Figure 2).



Figure 1. *Solanum nigrum* - Black nightshade © Used with permission. Photo Credit: Robin Slaughter.



Figure 2. *Solanum nigrum* - Black nightshade © Used with permission. Photo Credit: Robin Slaughter.

Unfortunately, black nightshade is often mistaken for deadly nightshade (*Atropa belladonna*) due to the similar common names.² True deadly nightshade is extremely rare in New Zealand and the two plants can be easily distinguished as deadly nightshade has large bell-shaped brownish-purple flowers (Figure 3) instead of the star-shaped white flower of black nightshade. The berries of deadly nightshade are also green ripening to black, but are larger.²

Interestingly, unripe green berries of black nightshade have also been mistaken for peas and have sometimes been found in frozen vegetables.³



Figure 3. *Atropa Belladonna* – Deadly nightshade © Used with permission. Photo Credit: Robin Slaughter.

Toxin—Black nightshade contains solanine and other related glycoalkaloids. These are present in all parts of the plant, but highest concentrations are in the unripe green berries. These alkaloids are heat stable, and not degraded by most cooking methods.⁴ In addition to black nightshade, a further 1,700 species of the *Solanum* genus also contain solanine and related alkaloids.⁵

The more commonly encountered species include bitterweet (*Solanum dulcamara*), egg plant (*Solanum melongena*), potato (*Solanum tuberosum*) and tomato (*Solanum lycopersicum*).⁵ The poisonous parts of the potato plant include the green berries, green tubers, flowers, leaves and seeds. However, fresh potato tubers are considered

non-poisonous. While the tomato has an edible fruit, the other parts of the plant are considered potentially toxic.^{6,7}

Mechanism of action—The toxic mechanism of solanine is not well described. *In vitro* studies have suggested that solanines are reversible inhibitors of human acetylcholinesterase (AChE) and pseudo or butyrylcholinesterase (pChE).⁸ However, this is of uncertain relevance as solanine toxicity is not typically associated with classic cholinergic symptoms.⁷ Rather, the symptoms displayed may reflect competing effects at nicotinic and muscarinic sites.⁹

Signs and symptoms—Black nightshade is not highly toxic and small accidental ingestions of a few berries or leaves does not often lead to symptoms. Toxicity would only be expected following ingestion of large amounts of unripe berries or other plant matter, i.e. in the situation of mistaking the plant for a food plant and ingested a meal sized portion.

Symptoms of solanine poisoning are most common following ingestion and are typically gastrointestinal and neurological in nature.⁷ Mild poisoning may involve nausea, vomiting, diarrhoea, anorexia, malaise, fever, headache and/or sweating.⁹⁻¹¹

In severe poisonings further symptoms are possible and may include hallucinations, delirium, drowsiness, ataxia, blurred vision, slurred speech, weakness, paraesthesia, facial numbness or paralysis, coma and respiratory muscle weakness, with risk of respiratory failure.^{9,10} Hypotension or bradycardia may occur, possibly secondary to gastrointestinal symptoms. The effects of poisoning are usually delayed in onset for at least 6 hours, and may in some instances be delayed for up to 20 hours post-ingestion.^{7,9,10,12}

Treatment—There is no specific antidote for solanine poisoning, and treatment is supportive.⁷ There is limited information on the benefit or otherwise of gastrointestinal decontamination with activated charcoal.⁷ As supportive care is likely to produce a good outcome, the risks of adverse effects from administration of activated charcoal likely outweigh any benefit and it is therefore not recommended.

The most common serious complication of solanine poisoning is dehydration and marked electrolyte imbalance from excessive vomiting and diarrhoea.⁷ Fluid and electrolyte balance should be monitored in symptomatic patients; intravenous fluid and electrolyte administration may be necessary.⁷ With marked dehydration, sweating mechanisms may become impaired, with potential aggravation of any fever and risk of hyperthermia requiring external cooling measures.

Neurological effects including delirium, hallucinations or anxiety can generally be managed without pharmaceutical intervention by placing the patient in a quiet, safe and darkened environment and by conversing in a calm and reassuring manner. Benzodiazepines may be required for significant delirium or agitation;¹⁰ however, caution is indicated as they may exacerbate any central nervous system (CNS) and/or respiratory depression. Coma, respiratory weakness and potentially life threatening respiratory failure are rare complications; intubation and mechanical ventilation may be required.⁹

Oxalate-containing plants

- **Arum Lily** (*Zantedeschia aethiopica*)
- **Peace Lily** (*Spathiphyllum* spp.)
- **Taro** (*Colocasia esculentum*)
- **Rhubarb** (*Rheum rhabarbarum*)

The most common oxalate-containing plants reported to the NZNPC are the arum lily (*Zantedeschia aethiopica*), peace lily (*Spathiphyllum* spp.), taro (*Colocasia esculentum*) and rhubarb (*Rheum rhabarbarum*).

Description—Arum lily (*Zantedeschia aethiopica*), peace lily (*Spathiphyllum* spp.) and taro (*Colocasia esculentum*) all belong to the Araceae or arum family, whereas rhubarb (*Rheum rhabarbarum*) belongs to the Polygonaceae family.

The arum lily is an evergreen perennial growing up to one metre in height. It has large green leathery arrow-shaped leaves and distinctive white funnel-shaped flowers containing a bright yellow spike¹³ (Figure 4). Peace lilies are evergreen perennials with large shiny green leaves and distinctive flowers consisting of a spike (spadix) surrounded by white, yellowish, or greenish leaf-like sheathing bract (spathe) (Figure 5).¹⁴ Taro is a herbaceous perennial growing 1 to 2 metres tall. It has large arrowhead-shaped green leaves on the end of large stalks.¹⁴ (Figure 6). Rhubarb is a herbaceous perennial plant; growing from a thick rhizome, it has large fan-shaped leaves on a long thick reddish leaf stalk.¹⁴ (Figure 7).



Figure 4. *Zantedeschia aethiopica* - Arum lily © Used with permission. Photo Credit: Robin Slaughter.



Figure 5. *Spathiphyllum* spp. - Peace lily © Used with permission. Photo Credit: Robin Slaughter.



Figure 6. *Colocasia esculentum* – Taro. Used with permission, Richard A. Howard Image Collection, courtesy of Smithsonian Institution.



Figure 7. *Rheum rhabarbarum* – Rhubarb © Used with permission. Photo Credit: Robin Slaughter.

Toxin—The major toxic components of these plants are oxalate compounds. Many different plant families and species contain oxalates; these can be present as insoluble compounds, usually calcium oxalate, or as soluble compounds, such as oxalic acid. The insoluble calcium oxalate salt is found in arum lilies, peace lilies and taro. Rhubarb leaves contain oxalic acid.¹⁵

Mechanism of action—Insoluble oxalate-containing plants have spindle-shaped cells named idioblasts containing needle-shaped crystals of calcium oxalate called raphides,¹⁶ which may also be coated with a proteolytic enzyme.^{17, 18} When the plant is crushed or chewed, the idioblasts are ruptured, and the sharp insoluble crystals and protease are injected into surrounding tissue structures such as the oral mucosa, tongue and throat.^{17, 19}

The symptoms produced are thought to arise from mechanical injury from the calcium oxalate crystals, along with the chemical action of the proteolytic enzyme, which is thought to stimulate bradykinin and histamine release.^{20–22}

Soluble oxalates or oxalic acid, on the other hand, have less of a local effect but can bind more effectively with ionised calcium in the blood or tissues. Following large ingestions, there is a potential risk of hypocalcaemia with associated systemic effects. In addition, significant amounts of calcium oxalate may precipitate in organs such as the kidney, heart, lungs and liver.^{23, 24}

Signs and symptoms—Plants containing the insoluble oxalates are more commonly responsible for human poisoning, but rarely cause significant systemic toxic effects.^{25, 26} Exposures are most common following ingestion (Table 2). The plant typically needs to be crushed, chewed or masticated to produce a local reaction; brief sucking on a leaf is not likely to cause toxicity.

Following oral exposure, initial symptoms typically develop within five minutes; they can include transient local irritation or a burning sensation of the oral mucosa and occasionally vomiting.^{25, 27} Symptoms typically do not progress from these initial mild effects, as the prompt reaction in the mouth generally limits the amount of plant material ingested.²² However, in some instances, intense burning pain and oedema of the mouth, tongue and throat, increased salivation, dysphagia, ulceration and aphonia may occur.^{19, 27, 28} Upper airway compromise and respiratory distress may occur if oropharyngeal oedema develops.²⁸

Soluble oxalates have a lesser local irritant effect, but may cause gastrointestinal upset following ingestion.²⁴ In humans, systemic effects from soluble oxalates have not been well documented, as there have been very few reports. These reports typically relate to large meal sized amounts consumed misguidedly as a food, producing renal dysfunction and hypocalcaemia.^{23, 24, 29} The former includes nephrocalcinosis, urolithiasis and renal insufficiency.²³

Reported complications from hypocalcaemia include paraesthesias, tetany, hyperreflexia, muscle fasciculations and seizures.^{29, 30} Older case reports, which attribute death to soluble oxalate-containing plants,³¹ may have overlooked other contributing factors.³²

Adverse effects in humans are also recognised from other routes of exposure. Eye contact with sap or other plant matter may lead to immediate pain, lacrimation,

photophobia, blepharospasm and a foreign body sensation.^{27, 33, 34} Crystals have been noted in the conjunctiva and on the corneal epithelium;³³⁻³⁵ injury to the latter may also include keratitis, corneal abrasions and areas of local necrosis.³⁶

Skin exposure to calcium oxalate-containing plants is typically of minor concern, usually only resulting in minimal symptoms. However, reported effects in sensitive individuals include pruritis, oedema and/or pain.²⁷ Irritant contact dermatitis may occur in people who frequently handle these plants.³⁷

Treatment—In the majority of cases, only mild symptoms develop and specific management is unlikely to be necessary. Milk and/or ice have been recommended to relieve local oral effects;^{25, 30, 38} ice blocks/popsicles may be useful in children.²² Simple analgesics such as paracetamol may be required if pain is significant.³⁸ Gastrointestinal decontamination with activated charcoal or other methods is not recommended, as it is unlikely to be of significant benefit.³⁰

With ingestion of insoluble oxalate plant matter, there is a risk of oedema of the oral cavity, pharynx and nearby structures.³⁸ Therefore, the airway and breathing should be monitored in symptomatic patients; in the case of upper airway compromise, intubation to maintain airway patency may be required.²⁸ Endoscopy may be necessary for patients with oral ulceration or dysphagia.³⁹

Clinical benefits from antihistamines for mucosal oedema have not been shown and these are therefore not recommended.³⁸ Significant vomiting may require supportive care, including fluid resuscitation and anti-emetic administration. Ensuring adequate hydration also promotes the renal excretion of calcium oxalate.³⁰

Systemic symptoms do not appear common, but if they develop, monitoring of full blood count, serum electrolytes including calcium, and kidney function is recommended. Oxalate-induced hypocalcaemia does not often require treatment unless the patient is symptomatic, in which case it should be treated with IV calcium gluconate with cardiac monitoring. Deteriorating renal function may require supportive care including haemodialysis.³⁰

Ocular exposures should receive thorough decontamination with water or saline for 15 minutes. Fluorescein-staining and slit lamp examination is recommended. Pain and/or inflammation may require cycloplegics and/or steroids.^{33, 34} Ophthalmological consultation should be arranged if there are significant abnormalities.

Skin exposure should be decontaminated with soap and water²² and any irritant contact dermatitis should be treated symptomatically.

Nicotinic plants

- **Kowhai** (*Sophora* spp.)
- **Hemlock** (*Conium maculatum*)

The plants kowhai and hemlock both contain alkaloids structurally related to nicotine. The similar symptoms produced are due to nicotinic receptor agonism.

Description—The common name kowhai refers to a number of species of *Sophora* in New Zealand, with *S. microphylla* being one of the most common.² *S. microphylla* trees are 3 to 9 m tall with a trunk 30 to 60 cm in diameter. Flowering occurs between

August and October; flowers are yellow and up to 4.5 cm long in 4 to 10 flowered racemes.^{2, 40} (Figure 8). They are found in open forests, forest outskirts, along rivers and in open places throughout both the North and South Island.^{2, 40}



Figure 8. *Sophora microphylla* – Kowhai © Used with permission. Photo Credit: Robin Slaughter.



Figure 9. *Conium maculatum* – Hemlock © Used with permission. Photo Credit: Robin Slaughter.

Hemlock (*Conium maculatum*) is an annual, biennial, or perennial erect, branched plant which can reach 2 m in height. Growing from a thick yellow or white tap root, the stem is hairless, rigid and hollow with characteristic irregular purple blotches (Figure 9).^{41, 42} The leaves are up to 30 cm long, triangular with finely divided leaflets, giving the plant a fernlike appearance. Flowers are white, small (2 mm diameter) and arranged in clusters. Each cluster is 2 to 5 cm in diameter.^{41, 42} (Figure 9).

Toxin—It is thought all parts of *Sophora* plants contain toxic alkaloids, particularly the seeds.^{2, 43} The major alkaloid is cytisine; other related alkaloids include N-

methylcytisine, anagyrine, matrine, sophoramine and sophochrysin.² These alkaloids are structurally similar to nicotine and act likewise, as nicotinic receptor agonists.^{41, 44}

Hemlock contains a number of piperidine alkaloids throughout the plant; the two found in the largest amounts, and accounting for most of the plant's toxic activity, are coniine and gamma-coniceine.^{41, 45} The name hemlock is also applied to, and may be confused with, the North American plant water hemlock (*Cicuta maculata*) which, however, is not found in New Zealand.⁴⁶

Mechanism of action—Structurally related to nicotine, the above alkaloids affect the neuromuscular junction where they act as non-depolarising neuromuscular blockers.⁴⁷ They also act on the autonomic ganglia, with varying degrees of stimulatory and inhibitory (“biphasic”) effects, resembling those of nicotine.⁴¹

Signs and symptoms—Ingestion is the most common route of exposure to these plants (Table 2); however, significant effects following ingestion of kowhai leaves, flowers or seeds appear to be extremely rare as most exposures consist of the accidental ingestion of a few seeds. There do not appear to have been any confirmed cases of significant poisonings following kowhai ingestion in New Zealand.

Additionally, as the seeds have a very hard outer casing, this typically prevents the alkaloids from being released following ingestion. Only if the seeds have been crushed or soaked is poisoning anticipated; otherwise it is likely that they will pass through the gastrointestinal tract without causing toxicity.

Symptoms are likely to occur following ingestion of any amount of hemlock. Initial symptoms from these nicotinic plants may include gastrointestinal effects such as nausea, vomiting, abdominal pain and diarrhoea. Other frequent early signs include tremor, dizziness and pallor, and parasympathetic effects such as diaphoresis, salivation and bronchorrhea.^{41, 48, 49}

In severe cases, more marked neurological and cardiovascular dysfunction become apparent. The clinical picture may follow a biphasic pattern due to initial stimulation of nicotinic cholinergic receptors followed quickly by their inhibition. This can produce restlessness, muscle fasciculation, seizures, hypertension, tachycardia and tachypnoea, followed by hypotension, bradycardia and respiratory depression, and finally leading to coma, muscle paralysis, respiratory failure, dysrhythmias and cardiovascular collapse.^{41, 48-51}

Treatment—Medical attention for small accidental kowhai ingestions is not generally necessary unless symptoms are present. It can be difficult to distinguish toxic from non-toxic doses of hemlock, and there are several reports of significant poisoning following its ingestion, especially if mistaken for a food plant;⁴¹ thus medical assessment is recommended for any ingestion.

Supportive care is the mainstay of management with an emphasis on respiratory and cardiovascular support. Although the benefits are unproven, decontamination with activated charcoal can be considered in compliant patients presenting within one hour;⁵² however, supportive care measures should take precedence. Although there is no specific antidote, atropine can be useful for excessive parasympathetic effects such as bronchoconstriction and bronchorrhea, gastrointestinal hyperactivity and bradycardia.⁴¹

Significant vomiting requires anti-emetic treatment while monitoring fluid and electrolyte balance. Hypotension should be managed with intravenous fluids; refractory hypotension may require treatment with agents with vasopressor and/or inotropic properties.⁴¹

Agitation, muscular over-activity or seizures should be managed with benzodiazepines; however, the latter may contribute to respiratory depression, and close monitoring of respiratory status is required.⁴¹ Severe cases may progress to muscle paralysis, coma and respiratory failure, necessitating intubation and intensive respiratory support.⁴¹

Euphorbia

- *Euphorbia* spp.

Description—*Euphorbia* is a large genus encompassing about 1600 species. Generally they are annual or perennial herbs or shrubs, typically with flowers in terminal clusters, with alternate or opposite leaves of various shapes and sizes (Figure 10). The most common name for plants in this genus is “spurge”.¹⁵



Figure 10. *Euphorbia* spp. – Euphorbia © Used with permission. Photo Credit: Robin Slaughter.



Figure 11. *Euphorbia pulcherrima* – Poinsettia © Used with permission. Photo Credit: Robin Slaughter.

The poinsettia (*Euphorbia pulcherrima*) (Figure 11) is a well-known member of this genus and has been reported historically as being highly toxic following ingestion. However, a review of 22,793 poinsettia ingestions or dermal exposures in the United States found accidental inadvertent exposures typically lacked any adverse effects and the plant was not associated with any significant morbidity or mortality.⁵³

Toxin—All species of *Euphorbia* produce a milky white latex-like sap¹⁵ which contains complex diterpenoid euphorbol esters.⁴³

Mechanism of action—The sap of toxic *Euphorbia* species is highly irritating and may cause localised effects following ingestion, or eye or skin exposures.

Signs and symptoms—Ocular exposure to the sap is the most common enquiry regarding *Euphorbia* spp. plants (Table 2). The sap is a strong ocular irritant. Reports of eye contact have described immediate symptoms of burning or stinging pain with blurred vision, itching, swelling of the lids, a foreign body sensation, photophobia and decreased visual acuity.

Eye injuries may worsen over hours to days following exposure; clinical findings may range from mild keratoconjunctivitis to severe keratitis with stromal oedema, epithelial and anterior uveitis. Injuries may have delayed healing but typically resolve completely within 1 to 2 weeks.⁵⁴⁻⁵⁷

Skin exposure to the sap may lead to irritant contact dermatitis with erythema, oedema and formation of blisters and vesicles.^{58,59} Dermal effects usually occur after two to eight hours and increase in severity in the following twelve hours, but normally resolve over the next three to four days without scarring.⁵⁸

Reports of poisoning following ingestion are quite scarce. Symptoms are typically limited to local irritation; common effects include salivation, nausea, vomiting, diarrhoea and gastroenteritis.¹⁵ These are usually mild and resolve spontaneously with minimal treatment.

Systemic effects are poorly documented, as it is rare that more than a taste or mouthful is ingested due to the plant causing an unpleasant burning sensation to the oral mucosa. However, reported effects include dizziness, delirium, convulsions and systemic collapse; these effects are possibly a consequence of fluid losses and electrolyte imbalances from the initial GI symptoms.¹⁵

Treatment—Eyes exposed to the sap should be thoroughly irrigated with water or saline. As significant adverse effects can occur, all symptomatic patients should be referred to an ophthalmologist. Ocular antibiotics, steroids and/or mydriatic and cycloplegic agents may be required.⁵⁴⁻⁵⁷ Cases treated soon after injury typically have a good outcome,⁵⁵ while delayed treatment may lead to complications, with patients left with corneal scarring and decreased visual acuity.^{57, 60}

Following skin exposure, the major treatment is ensuring the exposed area has been well washed with water and a mild soap.⁵⁸ Patients may require analgesics or anti-inflammatory agents; any further treatment, such as for irritant contact dermatitis, is symptomatic and supportive.⁵⁸

Small one-off ingestions of a few leaves or an accidental taste of the sap is unlikely to require any specific treatment; gastrointestinal irritation is typically mild and self-

limiting. Larger ingestions may lead to more severe GIT effects with the possibility of systemic toxicity. Decontamination is unlikely to be of benefit due to anticipated gastrointestinal distress and is not recommended. There is no specific antidote and treatment consists of symptomatic and supportive care.

Vomiting and diarrhoea may lead to dehydration with hypovolaemia; fluid resuscitation and electrolyte replacement may be required.⁴³ Other systemic effects seem unlikely, but reported effects have included seizures and collapse; standard management of seizures with benzodiazepines and potentially barbiturates is recommended. Endo-tracheal intubation and assisted ventilation may on occasion be necessary for decreased level of consciousness, or upper airway compromise due to local swelling.

Purgative plants

- **Agapanthus** (*Agapanthus* spp.)
- **Daffodil** (*Narcissus* spp.)
- **Stinking Iris** (*Iris foetidissima*)

Agapanthus, daffodil and stinking iris are all purgative plants causing similar symptoms, mainly related to gastrointestinal disturbance.

Description—All members of the genus *Agapanthus* are broadly similar in appearance. The most common species in New Zealand is the South African native *Agapanthus praecox*. It is a perennial with rhizomatous roots, glossy green strap-shaped leaves and an umbel-shaped cluster of purple or white flowers¹⁴ (Figure 12).

Daffodils or jonquils belong to the genus *Narcissus*. Blooming in spring, daffodils have attractive flowers making them a popular garden plant. They have an underground bulb and grow from 15 to 45 cm in height, with long, flat, hollow green leaves. The flowers are usually single or in small groups, each having 6 petals with a trumpet-shaped corona in the middle of the flower. The outer petals are typically yellow or white with the corona being yellow, orange or red^{14, 43} (Figure 13).

Members of the *Iris* genus are perennials growing from bulbs or rhizomes. They grow 15 to 100 cm in height and have long, thin, sword-shaped leaves growing from the base of the plant. The flowers are large and showy, having three major petals, which come in a variety of colours.⁴³ A common species in New Zealand is the stinking iris (*Iris foetidissima*) which has violet-blue flowers and bright orange seeds⁶¹ (Figure 14).



Figure 12. *Agapanthus praecox* – Agapanthus © Used with permission. Photo Credit: Robin Slaughter.



Figure 13. *Narcissus* spp. – Daffodil © Used with permission. Photo Credit: Robin Slaughter.



Figure 14. *Iris foetidissima* - Stinking iris © Used with permission. Photo Credit: Robin Slaughter.

Toxin—The most toxic part of the *Agapanthus* plant appears to be the rhizome which contains saponins and sapogenins. Sapogenins isolated from the rhizomes include yuccagenin and agapanthogenin.⁶²⁻⁶⁴ *Narcissus* plants contain a number of heat-stable toxic alkaloids, the most common being lycorine.^{43, 65} The bulb appears to contain the highest concentrations of alkaloids.^{15, 65} Plants in the *Iris* genus contain a number of terpenoids which appear to be concentrated in the bulb and rhizome of the plant.⁴³

Mechanism of action—The irritancy of these toxic components, especially on gastric mucosa, is thought to be responsible for the purgative action.⁴³

Signs and symptoms—Following accidental ingestion of a few leaves or flowers, no effects or only minor gastrointestinal discomfort is anticipated; however, ingestions of larger amounts of plant material or ingestion of any amount of the bulb or rhizome may result in more severe effects including vomiting, diarrhoea, abdominal pain, shivering, lightheadedness and dizziness.^{43, 65, 66} Mild symptoms typically resolve over the course of a few hours.⁶⁵

In animals, following ingestion of large amounts of *Narcissus* plant material there have been reports of more severe systemic toxicity including sedation, lack of coordination, seizures, paralysis, hepatic degeneration and cardiovascular dysfunction.^{43, 65, 67} However, these effects have not been reported in humans for the typical amounts consumed.

Treatment—Significant toxicity is not expected following small ingestions of leaves and flowers, and treatment should not generally be necessary. Decontamination is unlikely to be of benefit due to anticipated gastrointestinal distress and is not recommended. The major effects are gastrointestinal in nature; symptomatic patients may require maintenance of fluids and electrolytes and potentially anti-emetic and/or antidiarrhoeal medications.⁴³

There may be a risk of hypotension as a result of hypovolaemia. IV fluids should restore blood pressure; however, if this is unsuccessful, a vasopressor may be necessary. In the unlikely event of significant CNS depression or seizures, management is supportive; airway protection, ventilatory support, and/or anticonvulsants may rarely be required. Most patients have a good outcome.⁶⁵

Cardiac glycoside-containing plants

- **Oleander** (*Nerium oleander*)
- **Foxglove** (*Digitalis purpurea*)

Foxglove and oleander belong to a class of plants containing cardiac glycosides. The mechanism of toxicity and symptoms produced are similar.

Description—Oleander (*Nerium oleander*) is an evergreen shrub with many slender stems near ground level, which can reach from two up to 8 m in height.^{2, 6} The leaves are a dark dull green and are leathery, tapered at both ends, with a prominent mid-rib^{2, 6} (Figure 15). The leaves are 7.5 to 20 cm in length and 1-2 cm wide.⁶ At the end of the branches are clusters of attractive flowers, typically white, pink or dark red;^{2, 6} each is about 4-8 cm in diameter, and funnel-shaped with five petals (Figure 16).^{2, 6}



Figure 15. *Nerium oleander* – Oleander © Used with permission. Photo Credit: Robin Slaughter.



Figure 16. *Nerium oleander* – Oleander © Used with permission. Photo Credit: Robin Slaughter.

Foxglove (*Digitalis purpurea*) is a biennial herb; it has an erect flowering stem that grows up to 1.5 m in height (Figure 17).^{2, 6} The leaves are arranged in a rosette with each leaf being oval in shape.⁶ The tip tapers and the leaves are covered in short, soft hairs, giving a greyish-green appearance.⁶⁸ The flowers appear on a single spike, with up to 50 per spike,⁶⁸ each flower being up to 4-5 cm in length.^{6, 68} The petals are typically purplish pink, but may be white.⁴² The inner portion of the petal may have purple or brown spots, with these sometimes being ringed with white⁶⁸ (Figure 18).

Toxin—Foxglove and oleander contain cardiac glycosides (termed cardenolides, they include digoxin, digitoxin, oleandrin). These have a characteristic structure consisting of a steroid nucleus joined to a lactone with attached sugar moieties.⁶⁹

Other plants which contain similar cardiac glycosides include lily of the valley (*Convallaria majalis*),⁷⁰ swan plants or milkweeds (*Asclepias* spp.),⁷¹ the yew tree (*Taxus baccata*),⁷² *Cerbera* plants⁷³ and yellow oleander (*Thevetia peruviana*).⁷⁴ Other cardiotoxic plants acting via different mechanisms include aconite and related cardiotoxic alkaloids (*Aconitum* spp.),⁷⁵ veratrum alkaloids (*Veratrum* spp.),⁷⁶ and grayanotoxins (mainly *Rhododendron* spp.).⁷⁷



Figure 17. *Digitalis purpurea* – Foxglove © Used with permission. Photo Credit: Robin Slaughter.



Figure 18. *Digitalis purpurea* – Foxglove © Used with permission. Photo Credit: Robin Slaughter.

Mechanism of action—Cardenolides inhibit normal function in the myocardium and cardiac conducting tissue. A major mechanism is their inhibition of membrane-bound sodium-potassium-ATPase, which normally exchanges extracellular potassium for intracellular sodium.^{78, 79} Inhibition causes decreased active transport of potassium into, and sodium out of, myocardial cells, producing hyperkalaemia and increased intracellular sodium concentrations.⁷⁹ The latter reduces the activity of the sodium-calcium exchange mechanism, which normally transfers calcium out of the cell in exchange for sodium.⁷⁸

The net effect is elevated cytosolic calcium which, while beneficial therapeutically in producing increased cardiac contractility,⁸⁰ can also have adverse effects.⁷⁹ Excess intracellular calcium changes the resting membrane potential of the cell sufficiently to increase the risk of spontaneous depolarisation (increased automaticity).⁸⁰

Another major effect involves the autonomic nervous system, with an increase in cardiac vagal tone and decreased sympathetic activity.⁷⁹ This decreases sinoatrial (SA) node firing and slows conduction through the atrioventricular (AV) node, often with significant AV block; the His–Purkinje system is similarly affected.⁷⁸⁻⁸⁰ The combination of slowed normal impulse formation and conduction, but increased excitation and automaticity elsewhere, risks a range of dysrhythmias.⁷⁹ A third key factor can be hyperkalaemia, which also decreases normal impulse production and propagation.⁸¹

Signs and symptoms—Exposures to oleander and foxglove are most commonly reported following ingestion (Table 2). Symptoms are rapid in onset following ingestion of tea extracts,⁸² whereas they can be delayed for up to 2 to 3 hours after consumption of raw cardiotoxic plant matter.⁸³

Significant inter-individual differences in effect severity are reported, so that the clinical course can be difficult to predict;⁸⁴ the estimated ingested dose of oleander plant matter in a fatal case was reported to be 4 g of leaves,⁸⁵ whereas another patient suffered only mild cardiovascular effects, with full recovery, after ingesting “five handfuls” of oleander leaves.⁸⁶

Cardiac effects, albeit subclinical, have also been reported in four patients following the application of yellow oleander extract paste to ulcers, on alternate days for either one or two weeks.⁸⁷ Any amount of cardiac glycoside-containing plant material could potentially produce symptoms, especially in children.

Following ingestion, initial symptoms typically include nausea, vomiting, abdominal pain and diarrhoea.^{82, 88, 89} There may also be CNS effects including disturbed colour vision, drowsiness, dizziness, weakness, confusion and delirium. Reported adverse cardiac effects encompass almost any kind of dysrhythmia, including sinus bradycardias (and arrest), atrial flutter/fibrillation, various degrees of AV block, junctional rhythms, and ventricular tachycardia; sudden ventricular fibrillation or asystole can also occur.^{73, 74, 79, 90-94} Hyperkalaemia is a hallmark of cardioglycoside toxicity, and serum potassium concentrations typically correlate well with the severity of acute poisoning.⁹²

Treatment—Decontamination with activated charcoal can be considered if this can be administered safely within an hour of ingestion.^{52, 95} There are limited data, but activated charcoal appears to have a favourable effect on the disposition of cardiac glycosides in acute yellow oleander (*Thevetia peruviana*) self-poisoning by reducing terminal half-life and mean residence time.⁸⁴

Multiple dose activated charcoal (MDAC) has also been investigated as a treatment for poisoning by this plant, but two methodologically different studies had discordant findings, making a firm recommendation difficult.⁷⁴ In one single-blind, randomised, placebo-controlled trial, MDAC was found to reduce life-threatening dysrhythmias and deaths.⁹⁶ However, a later open-label, parallel group, randomised controlled study reported no reduction in mortality in those treated with either single dose, multiple dose, or no charcoal.⁹⁷ Gastric lavage is not recommended due to the risk of further vagal stimulation and ventricular fibrillation or asystole.⁷⁹

Patient monitoring should include an ECG and fluid and electrolyte assessment, including potassium, calcium and magnesium concentrations;^{78, 95} hypomagnesaemia

may worsen toxicity.⁷⁴ Anti-emetics should be used to control vomiting and thus reduce levels of vagal stimulation; intravenous metoclopramide is recommended initially to control vomiting but a 5HT₃ antagonist such as intravenous ondansetron may be necessary if initial treatment is unsatisfactory.⁷⁴ Fluid replacement may also be required.

The mainstay of treatment is use of digoxin-specific antibody fragments (digoxin-Fab).⁹⁸ Data suggest it can be rapidly effective for reversing the effects of digoxin;⁹⁹ observational data^{83, 88} and one randomised controlled trial suggest it is also effective for cardiac glycoside-containing plants.¹⁰⁰ It is recommended in patients with life-threatening dysrhythmia, haemodynamic compromise, or serum potassium greater than 5.5 mmol/L (5.5 mEq/L).⁹⁵

The optimum dose for plant cardiac glycoside poisoning is unclear, but a relatively high initial dose of 800 mg (20 vials) is recommended, due to possible lower binding affinity of digoxin-Fab to natural cardiac glycosides than to digoxin.¹⁰⁰

With digoxin, it has been suggested to commence Fab treatment if serum concentrations are greater than 10 nmol/L (7.8 ug/L) at 6 hours post-ingestion.⁷⁸ However, assays originally designed to measure serum digoxin concentrations are of limited use for plants such as oleander, as such assays are only semiquantitative for other digoxin-like substances, and may misrepresent their concentrations.⁸⁵

In the absence of digoxin-Fab, meticulous supportive care is required. Cardiology consultation is strongly advised for patients with hemodynamically significant arrhythmia.⁹⁵ In those where a substantial dose is suspected, the appropriate standard of care should include continuous ECG monitoring in an Intensive Care or Coronary Care area with availability of defibrillator equipment.

Bradyarrhythmias have been treated with atropine, catecholamines (such as isoprenaline and salbutamol) and/or temporary cardiac pacing. There is limited information on the relative efficacy and safety of these compounds, though catecholamines present an increased risk of tachyarrhythmias.

Atropine is most commonly recommended for bradycardia (<40 bpm)^{79, 95, 96} which is consistent with the known role of vagally mediated mechanisms. It can be titrated to maintain heart rates between 60 and 90 bpm.⁷⁴ Many patients will tolerate a relative bradycardia and can be managed without intervention for heart rates 40-50 bpm, provided they remain haemodynamically stable with maintained blood pressure and perfusion.

Temporary transvenous pacing remains the mainstay of managing severe persistent bradycardia (usually complete AV block or profound sinus bradycardia or arrest) particularly when associated with syncope or haemodynamic collapse.⁷⁴ Temporary cardiac pacing for severe bradycardia or ventricular dysrhythmia may be avoided when digoxin-Fab is available.

Cardiac pacing should not be routinely instituted for stable clinical situations, as the benefits of placing a transvenous pacing wire should be weighed against the possible risks of the wire causing mechanical stimulation of irritable myocardium, and thus increasing the risk of induced ventricular dysrhythmia;¹⁰¹ there is also the risk of myocardial perforation.⁹⁵

Magnesium sulphate may be useful for ventricular tachydysrhythmias.^{98, 102, 103}

Lignocaine can also be useful for first and second degree AV block, some supraventricular bradydysrhythmias, ventricular ectopics, bigeminy, and ventricular tachydysrhythmias.^{90, 93, 104} It has been suggested that cautious use of phenytoin (a class 1B antiarrhythmic agent) may be of benefit for resistant dysrhythmias,¹⁰⁵ but this agent is no longer favoured in the acute poisoning setting. Class 1A and 1C agents should be avoided due to their adverse impact on AV-nodal conduction.⁷⁸

When marked ventricular irritability is seen (frequent multifocal ectopics or runs of non-sustained ventricular tachycardia) a defibrillator should be close to the patient, and wearable defibrillator pads placed in readiness on the chest wall, to manage ventricular fibrillation should it occur.

Theoretically, electrical cardioversion is relatively contraindicated in the presence of cardiac glycoside toxicity, as it can result in asystole or ventricular fibrillation,^{80, 93} though the latter may respond to low energy cardioversion.⁹⁵ The use of cardioversion to manage low risk arrhythmias, such as atrial fibrillation, should be avoided in this setting. Prompt cardioversion for ventricular fibrillation is the only appropriate life-saving medical intervention possible.

Potassium concentrations greater than 5.5 mmol/L (5.5 mEq/L) should initially be managed with digoxin-Fab,⁹⁵ but in its absence IV insulin-dextrose may be beneficial.⁷⁴ Sodium bicarbonate may not prove beneficial for hyperkalaemia, and polystyrene sulfonate is not advised as it may precipitate hypokalaemia, especially if it is given with digoxin-Fab.⁷⁴ Furthermore, calcium is typically not recommended for hyperkalaemia, due to the theoretical risk that it may further increase myocardial calcium load and enhance risks of dysrhythmia.^{80, 106} Although the use of calcium in the situation of cardiac glycoside toxicity may not be as detrimental as previously thought,¹⁰⁷⁻¹⁰⁹ its use in cardiac glycoside poisoning remains controversial until more definitive studies are conducted.¹¹⁰ Haemodialysis may be necessary for particularly severe hyperkalaemia or in the renally impaired;^{93, 111} however, neither this nor other extracorporeal methods are effective in removing cardiac glycosides from the blood.⁹³

Karaka

- **Karaka (*Corynocarpus laevigatus*)**

Description—Karaka (*Corynocarpus laevigatus*) is a native evergreen, growing 9–15 m tall. (Figure 19) It has thick, glossy, dark green leaves, oblong in shape and 10–15 cm in length. The small flowers are greenish-yellow while the fruits are elliptical, bright orange when ripe and 25-40 mm long. (Figure 20.). Each fruit contains a large kernel (seed).²

Toxin—This plant contains the toxin karakin, which upon hydrolysis yields the toxic metabolite 3-nitropropionic acid (3-NP).¹¹² 3-NP and its precursors are also found in other species of plants including timber milkvetch (*Astragalus mise*); it is also produced by a fungus (*Arthrimum* spp.) which is associated with mouldy sugarcane.¹¹³

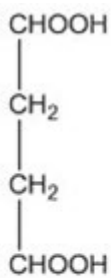


Figure 19. *Corynocarpus laevigatus* – Karaka © Used with permission. Photo Credit: Robin Slaughter.

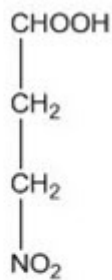


Figure 20. *Corynocarpus laevigatus* – Karaka © Used with permission. Photo Credit: Robin Slaughter.

Karakin is most concentrated in the kernel; however, this can be rendered non-toxic by heating to above 100° C for at least 4 to 6 hours.^{2, 114} It was a principal source of food for Maori, who prepared it for human consumption by heating then washing the fruit.^{115, 116}



Succinic acid



3-Nitropropionic acid

Figure 21. The chemical structure of succinic acid and 3-nitropropionic acid.

Mechanism of action—3-NP structurally resembles succinic acid (“succinate”) (Figure 21), a natural substrate within the Krebs (tricarboxylic acid) cycle which

contributes to ATP synthesis within mitochondria. 3-NP competes for, and effectively irreversibly inhibits, the enzyme succinate dehydrogenase (SDH),^{117, 118} which converts succinate to fumarate (the next step in the cycle). This will inhibit the cycle, and thereby interfere with ATP synthesis and cellular energy production, while also causing an accumulation of succinic acid and lactate, the latter arising from a shift towards more anaerobic metabolism.¹¹⁷

Other consequences may arise from compromised mitochondrial function, including oxidative stress due to the increased production of free radicals, such as super-oxide, hydroxyl radical and peroxynitrite.¹¹⁷ In addition, excitotoxic and neurodegenerative effects can occur secondary to inhibition of ATP-dependent ion pumps.

Calcium, which enters the cell during depolarisation, cannot be removed from the cell due to a lack of ATP-dependent ion transport, leading to calcium overload and subsequent apoptosis and necrosis of glutamatergic neurons.¹¹⁷ Such effects can lead to delayed neurodegeneration within the basal ganglia, associated with cognitive and motor deficits, which are characterised by hypokinesia, dystonia and chorea.^{117, 119}

Signs and symptoms—The majority of reported exposures to karaka are following ingestion (Table 2). While an exact toxic dose is unknown, it is thought that any ingestion of the kernel could potentially produce signs and symptoms. However, the leaves and skin of the berry contain less toxin and the ingestion of a few of the leaves or the berry skin is therefore unlikely to lead to poisoning.

Nausea, vomiting, diarrhoea and abdominal pain typically occur early in the course of poisoning;^{113, 119} they may be accompanied by headache, drowsiness, fever, nystagmus, aphasia, dizziness and lethargy. More severe acute symptoms include tremor, seizures, coma, respiratory depression and respiratory arrest.^{113, 115, 119, 120}

Another major concern following poisoning is possible neurodegenerative damage, which can be delayed and may resemble symptoms of Huntington's disease. The most common manifestation is dystonia; other effects may include choreoathetoid movements and dyskinesia.^{113, 119, 121}

The onset of neurodegenerative damage may be delayed for 2 to 4 weeks post-ingestion, especially in children,¹¹³ and damage may not resolve completely.^{113, 119} CT or MRI scans have shown hypodensity in the basal ganglia,^{113, 119} commonly in the putamen and globus pallidus, and occasionally in the caudate nucleus.¹¹⁹ Furthermore, while not reported in humans, reports of poisonings in cattle, sheep and rabbits have described methaemoglobinaemia, likely secondary to the liberation of nitrite.^{120, 122}

Treatment—As the most toxic part of the plant is the kernel, any ingestion of this part warrants medical attention and observation. Small accidental ingestions of other plant matter are unlikely to cause serious toxicity and in this situation medical attention is not generally necessary unless symptoms are present.

There are no specific antidotes, with the mainstay of management being symptomatic and supportive care. Initial treatment includes activated charcoal, which should ideally be administered within an hour of ingestion.⁵² Moderate to severe poisoning commonly leads to seizures;^{113, 119} these will typically resolve spontaneously, but can be managed initially with a benzodiazepine or, if still refractory, a barbiturate.

Persistent vomiting or diarrhoea may require treatment with anti-emetic drugs and adequate fluid and electrolyte replacement.

Neurodegenerative lesions in the striatum may manifest as dystonia and/or athetosis. There is no known treatment for these symptoms; levodopa does not appear to be helpful,¹¹³ and there is no information regarding whether conventional management for dystonia such as benztropine or diphenhydramine is effective. It is possible patients may, in rare instances, recover, but dystonia is generally permanent.¹¹³

While in humans methaemoglobinaemia appears just a theoretical concern, it should be monitored for, and if elevated managed along usual guidelines, with methylene blue if indicated.¹²³

Stinging nettle plants

- **Ongaonga (*Urtica ferox*)**

Description—Commonly known as ongaonga or New Zealand tree nettle, *Urtica ferox* is a native species of stinging nettle.¹²⁴ It is a shrub which may grow up to 2 m or more in height. It has pale green leaves, 8–12 cm in length, and triangular in shape with coarsely toothed margins.



Figure 22. *Urtica ferox* - Ongaonga/New Zealand tree nettle © Used with permission. Photo Credit: Robin Slaughter.

The leaf surfaces and leaf stalks and stems carry fine, pointed, white stinging hairs named trichomes, which are tapered capillary tubes rising from a bulbous base to a small spherical tip, which may be 5–6 mm in length^{2,125} (Figure 22).

Toxin—The trichomes of ongaonga contain a liquid which include the active components acetylcholine, histamine and serotonin.^{124,126}

Mechanism of action—When in contact with the skin, the trichome tip breaks off, exposing a fine needle-like point which penetrates the skin. The base of the trichome also becomes compressed, which forces the fluid in the bulb through the tube and into the tissue.¹²⁵

It appears that acetylcholine and histamine are responsible for the local effects; histamine, in association with serotonin, may also activate nociceptive pain neurons.

Kinins and leukotrienes may also be released, contributing to pain and inflammation. However, this does not readily explain all the effects described, and it is likely additional substances capable of secondary release, or an as yet unidentified neurotoxic agent, may contribute.^{124, 127}

Signs and symptoms—The majority of reported exposures to ongaonga are following skin contact (Table 2); following even the slightest contact with the stinging hairs, intense pain with itching, inflammation, paresthesia, dermatitis and urticaria can quickly occur.^{124, 128} Local effects may last for 12 to 36 hours or longer.¹⁵

If a large surface area is involved, systemic symptoms may also occur. These may include abdominal pain, salivation, visual disturbances, paresthesia, muscle weakness, cramps, lack of co-ordination, paralysis and respiratory difficulties.^{124, 128} Systemic symptoms typically onset within 30 minutes and can last for 24 hours or longer, potentially for weeks.^{2, 124, 128}

The urticaria is typically non-immunological; however, immediate hypersensitivity reactions, including systemic anaphylactic effects, while not well described with ongaonga, have occasionally been reported with other species of stinging nettle.^{129, 130} These are presumed IgE-mediated reactions, though a delayed skin reaction has also been reported.^{129, 130} Peripheral neuropathy may also rarely occur, with slow resolution of some symptoms and nerve conduction study findings.¹²⁴

There is one anecdotal case reported of a fatality following an ongaonga sting in New Zealand. A hunter walked through a patch of nettle and approximately 1 hour post-exposure developed symptoms of stomach ache, difficulty breathing and paralysis. The patient was transported to medical care but died 5 hours post-exposure.²

Treatment—The primary goal following ongaonga exposure is timely treatment of local effects. The area should be promptly flushed with water, and local pain and itching relieved by cooling with ice packs and/or applying a moistened cloth. Oral analgesics, antihistamines and/or anti-inflammatories may also be necessary to alleviate pain, pruritis and inflammation. In the majority of cases involving brief dermal exposure, the effects are relatively mild and self-limiting, and do not require further specific therapy.¹³¹

If systemic symptoms are evident, more intense supportive care may be required. Muscle weakness, paralysis or respiratory insufficiency requires priority management, including close monitoring of airway function; intubation with respiratory support is recommended in significantly symptomatic patients. In the event of hypersalivation contributing to compromised upper airway patency, atropine as well as suctioning may be helpful.

Serious anaphylactic (or possibly anaphylactoid) reactions should be treated in the usual manner with attention to the airway, breathing and circulation, along with immediate administration of adrenaline.

Conclusions

New Zealand is host to a number of poisonous plants, both native and introduced. The NZNPC frequently receives enquiries regarding plant exposures. The majority of human exposures cause only minor symptoms, and serious poisoning is rare.

However, there are some plants, when ingested in sufficient quantity, which are capable of causing severe poisoning.

Accurate plant identification can be important as a preventive measure, as well as being central to determining the likely risk of adverse effects. Plant identification can be difficult in some situations, but plant books, commercial garden centres, botanical gardens or University botany departments may be helpful for accurately clarifying the species involved.

In the absence of definitive plant identification, management of poisoning relies on appropriate first aid, close monitoring of evolving clinical features, and management along the lines discussed in this review.

First aid following plant exposures

If it is suspected that exposure to a potentially poisonous plant has occurred first aid measures include:

Following ingestion: Remove any remaining plant material and rinse mouth

Following eye exposure: irrigate the eye with gently running water for minimum of 15 minutes

Following skin contact: Gently rinse the skin with running water

Phone the Poisons Centre on 0800 764 766 for further specific information.

Competing interests: Nil.

Author information: Robin J Slaughter, Poisons Information Officer; National Poisons Centre, University of Otago, Dunedin; D Michael G Beasley, Medical Toxicologist, National Poisons Centre, University of Otago, Dunedin; Bruce S Lambie, Consultant Emergency Physician, Emergency Department, Dunedin Hospital, Dunedin; Gerard T Wilkins, Consultant Cardiologist, Associate Professor of Medicine, Department of Cardiology, Dunedin Hospital, Dunedin; Leo J Schep, Toxicologist, National Poisons Centre, University of Otago, Dunedin

Acknowledgement: We thank Justine Schep for copyediting the manuscript.

Correspondence: Robin J Slaughter; National Poisons Centre, University of Otago, PO Box 913, Dunedin, New Zealand. Fax: +64 (0)3 4770509; email: robin.slaughter@otago.ac.nz

References:

1. Meredith TJ. Epidemiology of poisoning. *Pharmacol Ther.* 1993;59:251-6.
2. Connor HE. *The poisonous plants in New Zealand.* Wellington, New Zealand: Crown Copyright; 1977.
3. Schep LJ, Slaughter RJ, Temple WA. Contaminant berries in frozen vegetables. *N Z Med J.* 2009;122:95-6.
4. Dinkins CL, Peterson RK. A human dietary risk assessment associated with glycoalkaloid responses of potato to Colorado potato beetle defoliation. *Food Chem Toxicol.* 2008;46:2837-40.

5. Palmer M, Betz JM. Plants. in Goldfrank's toxicologic emergencies, Flomenbaum NE, Goldfrank LR, Hoffman RS, Howland M, Lewin NA, Nelson LS, eds. New York:McGraw-Hill; 2006.
6. Everist SL. Poisonous plants of Australia. Sydney:Angus & Robertson Publishers; 1974.
7. Barceloux DG. Potatoes, tomatoes, and solanine toxicity (*Solanum tuberosum* L., *Solanum lycopersicum* L.). Dis Mon. 2009;55:391-402.
8. McGehee DS, Krasowski MD, Fung DL, et al. Cholinesterase inhibition by potato glycoalkaloids slows mivacurium metabolism. Anesthesiology. 2000;93:510-9.
9. Smith SW, Giesbrecht E, Thompson M, et al. Solanaceous steroidal glycoalkaloids and poisoning by *Solanum torvum*, the normally edible susumber berry. Toxicon. 2008;52:667-76.
10. McMillan M, Thompson JC. An outbreak of suspected solanine poisoning in schoolboys: Examinations of criteria of solanine poisoning. Q J Med. 1979;48:227-43.
11. Hansen AA. Two fatal cases of potato poisoning. Science. 1925;61:340-1.
12. Willimott SG. An investigation of solanine poisoning. Analyst. 1933;58:431-9.
13. Roy B, Popay I, Champion P, et al. An illustrated guide to common weeds of New Zealand. Christchurch, New Zealand: New Zealand Plant Protection Society (Inc); 1998.
14. Perry F. The Macdonald encyclopaedia of plants and flowers. London: Macdonald & Co; 1991.
15. Frohne D, Pfänder HJ. Poisonous plants. A handbook for doctors, pharmacists, toxicologists, biologists and veterinarians. Stuttgart:Wissenschaftliche Verlagsgesellschaft mbH; 2004.
16. Franceschi VR, Nakata PA. Calcium oxalate in plants: Formation and function. Annu Rev Plant Biol. 2005;56:41-71.
17. Rauber A. Observations on the idioblasts of *Dieffenbachia*. J Toxicol Clin Toxicol. 1985;23:79-90.
18. Kuballa B, Lugnier AA, Anton R. Study of *Dieffenbachia*-induced oedema in mouse and rat hindpaw: respective role of oxalate needles and trypsin-like protease. Toxicol Appl Pharmacol. 1981;58:444-51.
19. McIntire MS, Guest JR, Porterfield JF. Philodendron – an infant death. J Toxicol Clin Toxicol. 1990;28:177-83.
20. Gardner DG. Injury to the oral mucous-membranes caused by the common houseplant, *Dieffenbachia* – a review. Oral Surg Oral Med Oral Pathol. 1994;78:631-3.
21. Chitre A, Padmanabhan S, Shastri NV. A cysteine protease of *Dieffenbachia maculata*. Indian J Biochem Biophys. 1998;35:358-63.
22. Scalzo AJ. Overview of plant and herbal toxicity. in Critical care toxicology: Diagnosis and management of the critically poisoned patient, Brent J, Wallace KL, Burkhart KK, Phillips SD, Donovan JW, eds. Philadelphia (PA):Elsevier Mosby; 2005.
23. Chen CL, Fang HC, Chou K, et al. Acute oxalate nephropathy after ingestion of star fruit. Am J Kidney Dis. 2001;37:418-22.
24. Farre M, Xirgu J, Salgado A, et al. Fatal oxalic-acid poisoning from sorrel soup. Lancet. 1989;2:1524.
25. Mrvos R, Dean BS, Krenzelok EP. *Philodendron/Dieffenbachia* ingestions – are they a problem. J Toxicol Clin Toxicol. 1991;29:485-91.
26. Krenzelok EP, Jacobsen TD, Aronis JM. Plant exposures: A state profile of the most common species. Vet Hum Toxicol. 1996;38:289-98.
27. Pedaci L, Krenzelok EP, Jacobsen TD, Aronis J. *Dieffenbachia* species exposures: an evidence-based assessment of symptom presentation. Vet Hum Toxicol. 1999;41:335-8.
28. Cumpston KL, Vogel SN, Leikin JB, Erickson TB. Acute airway compromise after brief exposure to a *Dieffenbachia* plant. J Emerg Med. 2003;25:391-7.
29. Kalliala H, Kauste O. Ingestion of rhubarb leaves as cause of oxalic acid poisoning. Ann Paediatr Fenn. 1964;10:228-31.
30. Barceloux DG. Rhubarb and oxalosis (*Rheum* species). Dis Mon. 2009;55:403-11.

31. Robb HF. Death from rhubarb leaves due to oxalic acid poisoning. *J Am Med Assoc.* 1919;73:627-8.
32. Leffmann H. Death from rhubarb leaves due to oxalic acid poisoning. *J Am Med Assoc.* 1919;73:928-9.
33. Chiou AG, Cadez R, Bohnke M. Diagnosis of *Dieffenbachia* induced corneal injury by confocal microscopy. *Br J Ophthalmol.* 1997;81:168-9.
34. Tang EW, Law RW, Lai JS. Corneal injury by wild taro. *Clin Exp Ophthalmol.* 2006;34:895-6.
35. Rao SK, Kumar SK, Biswas J, et al. Self-induced corneal crystals – A case report. *Cornea.* 2000;19:410-1.
36. Seet B, Chan WK, Ang CL. Crystalline keratopathy from *Dieffenbachia* plant sap. *Br J Ophthalmol.* 1995;79:98-9.
37. Corazza M, Romani I, Poli F, Virgili A. Irritant contact dermatitis due to *Dieffenbachia* spp. *J Eur Acad Dermatol Venereol.* 1998;10:87-9.
38. Tagwireyi D, Ball DE. The management of Elephant's Ear poisoning. *Hum Exp Toxicol.* 2001;20:189-92.
39. Snajdauf J, Mixa V, Rygl M, et al. Aortoesophageal fistula – an unusual complication of esophagitis caused by *Dieffenbachia* ingestion. *J Pediatr Surg.* 2005;40:e29-e31.
40. Metcalf LJ. *New Zealand trees and shrubs.* Auckland: Reed Publishing Ltd; 2000.
41. Schep LJ, Slaughter RJ, Beasley DM. Nicotinic plant poisoning. *Clin Toxicol (Phila).* 2009;47:771-81.
42. Kingsbury JM. *Poisonous plants of the United States and Canada.* Englewood Cliffs (NJ):Prentice-Hall; 1964.
43. Burrows GE, Tyrl RJ. *Toxic plants of North America.* Ames (IA):Iowa State Press; 2001.
44. Dale HH, Laidlaw PP. The physiological action of cytisine, the active alkaloid of laburnum (*Cytisus laburnum*). *J Pharmacol Exp Ther.* 1912;3:205-21.
45. López TA, Cid MS, Bianchini ML. Biochemistry of hemlock (*Conium maculatum* L.) alkaloids and their acute and chronic toxicity in livestock. A review. *Toxicol.* 1999;37:841-65.
46. Schep LJ, Slaughter RJ, Becket G, Beasley DM. Poisoning due to water hemlock. *Clin Toxicol (Phila).* 2009;47:270-8.
47. Bowman WC, Sanghvi IS. Pharmacological actions of hemlock (*Conium maculatum*) alkaloids. *J Pharm Pharmacol.* 1963;15:1-25.
48. Manoguerra AS, Freeman D. Acute poisoning from the ingestion of *Nicotiana glauca*. *J Toxicol Clin Toxicol.* 1982;19:861-4.
49. Mellick LB, Makowski T, Mellick GA, Borger R. Neuromuscular blockade after ingestion of tree tobacco (*Nicotiana glauca*). *Ann Emerg Med.* 1999;34:101-4.
50. Biberci E, Altuntas Y, Cobanoglu A, Alpınar A. Acute respiratory arrest following hemlock (*Conium maculatum*) intoxication. *J Toxicol Clin Toxicol.* 2002;40:517-8.
51. Drummer OH, Roberts AN, Bedford PJ, et al. Three deaths from hemlock poisoning. *Med J Aust.* 1995;162:592-3.
52. Chyka PA, Seger D, Krenzelok EP, Vale JA. Position paper: Single-dose activated charcoal. *Clin Toxicol (Phila).* 2005;43:61-87.
53. Krenzelok EP, Jacobsen TD, Aronis JM. Poinsettia exposures have good outcomes...just as we thought. *Am J Emerg Med.* 1996;14:671-4.
54. Eke T, Al-Husainy S, Raynor MK. The spectrum of ocular inflammation caused by euphorbia plant sap. *Arch Ophthalmol.* 2000;118:13-6.
55. Scott IU, Karp CL. Euphorbia sap keratopathy: four cases and a possible pathogenic mechanism. *Br J Ophthalmol.* 1996;80:823-6.
56. Merani R, Sa-Ngiampornpanit T, Kerdraon Y, et al. *Euphorbia lactea* sap keratouveitis: case report and review of the literature. *Cornea.* 2007;26:749-52.

57. Sood GC, Sofat BK, Chandel RD. Injury to the eye by the sap of *Euphorbia royleana*. Br J Ophthalmol. 1971;55
58. Spoerke DG, Temple AR. Dermatitis after exposure to a garden plant (*Euphorbia myrsinites*). AMA Am J Dis Child. 1979;133:28-9.
59. Asilian A, Faghihi G. Severe irritant contact dermatitis from Cypress spurge. Contact Dermatitis. 2004;51:37-9.
60. Sofat BK, Sood GC, Chandel RD, Mehrotra SK. *Euphorbia royleana* latex keratitis. Am J Ophthalmol. 1972;74:634-7.
61. North P. Poisonous plants and fungi in colour. London: Blandford Press; 1967.
62. Mathew GE, Stephen T. The position of the tertiary hydroxyl groups in agapanthagenin. J Chem Soc. 1957;1957:262-4.
63. Gonzalez AG, Francisco CG, Freire R, et al. 9(11)-dehydroagapanthagenin, a new spirostan sapogenin from *Agapanthus africanus*. Phytochemistry. 1975;14:2259-62.
64. Snoeijer W. Agapanthus: a revision of the genus. Portland (OR):Timber Press, Ltd; 2004.
65. Litovitz TL, Fahey BA. Please don't eat the daffodils. N Engl J Med. 1982;306:547.
66. Spoerke DG, Smolinske SC. Toxicity of houseplants. Boca Raton (FL):CRC Press; 1990.
67. Saxon-Buri S. Daffodil toxicosis in an adult cat. Can Vet J. 2004;45:248-50.
68. Cooper MR, Johnson AW. Poisonous plants in Britain and their effects on animals and man. London: Crown Copyright; 1984.
69. Langford SD, Boor PJ. Oleander toxicity: an examination of human and animal toxic exposures. Toxicology. 1996;109:1-13.
70. Kopp B, Kubelka W. New cardenolides from *Convallaria majalis* [German]. Planta Med. 1982;45:195-202.
71. Radford DJ, Gillies AD, Hinds JA, Duffy P. Naturally occurring cardiac glycosides. Med J Aust. 1986;144:540-4.
72. Cummins RO, Haulman J, Quan L, et al. Near-fatal yew berry intoxication treated with external cardiac pacing and digoxin-specific FAB antibody fragments. Ann Emerg Med. 1990;19:38-43.
73. Eddleston M, Haggalla S. Fatal injury in eastern Sri Lanka, with special reference to cardenolide self-poisoning with *Cerbera manghas* fruits. Clin Toxicol (Phila). 2008;46:745-8.
74. Rajapakse S. Management of yellow oleander poisoning. Clin Toxicol (Phila). 2009;47:206-12.
75. Chan TY. Aconite poisoning. Clin Toxicol (Phila). 2009;47:279-85.
76. Schep LJ, Schmierer DM, Fountain JS. *Veratrum* poisoning. Toxicol Rev. 2006;25:73-8.
77. Gunduz A, Turedi S, Russell RM, Ayaz FA. Clinical review of grayanotoxin/mad honey poisoning past and present. Clin Toxicol (Phila). 2008;46:437-42.
78. Dawson A, Buckley N. Digoxin. Medicine. 2007;35:613-4.
79. Taboulet P, Baud FJ, Bismuth C. Clinical features and management of digitalis poisoning--rationale for immunotherapy. J Toxicol Clin Toxicol. 1993;31:247-60.
80. Ma G, Brady WJ, Pollack M, Chan TC. Electrocardiographic manifestations: digitalis toxicity. J Emerg Med. 2001;20:145-52.
81. Parham WA, Mehdirad AA, Biermann KM, Fredman CS. Hyperkalemia revisited. Tex Heart Inst J. 2006;33:40-7.
82. Haynes BE, Bessen HA, Wightman WD. Oleander tea: herbal draught of death. Ann Emerg Med. 1985;14:350-3.
83. Shumaik GM, Wu AW, Ping AC. Oleander poisoning: treatment with digoxin-specific Fab antibody fragments. Ann Emerg Med. 1988;17:732-5.
84. Roberts DM, Southcott E, Potter JM, et al. Pharmacokinetics of digoxin cross-reacting substances in patients with acute yellow Oleander (*Thevetia peruviana*) poisoning, including the effect of activated charcoal. Ther Drug Monit. 2006;28:784-92.

85. Osterloh J, Herold S, Pond S. Oleander interference in the digoxin radioimmunoassay in a fatal ingestion. *JAMA*. 1982;247:1596-7.
86. Tracqui A, Kintz P, Branche F, Ludes B. Confirmation of oleander poisoning by HPLC/MS. *Int J Legal Med*. 1998;111:32-4.
87. Senthilkumaran S, Saravanakumar S, Thirumalaikolundusubramanian P. Cutaneous absorption of oleander: Fact or fiction. *J Emerg Trauma Shock*. 2009;2:43-5.
88. Safadi R, Levy I, Amitai Y, Caraco Y. Beneficial effect of digoxin-specific Fab antibody fragments in oleander intoxication. *Arch Intern Med*. 1995;155:2121-5.
89. Saravanapavananthan N, Ganeshamoorthy J. Yellow oleander poisoning--a study of 170 cases. *Forensic Sci Int*. 1988;36:247-50.
90. Smith TW, Willerson JT. Suicidal and accidental digoxin ingestion. Report of five cases with serum digoxin level correlations. *Circulation*. 1971;44:29-36.
91. Mahdyoon H, Battilana G, Rosman H, et al. The evolving pattern of digoxin intoxication: observations at a large urban hospital from 1980 to 1988. *Am Heart J*. 1990;120:1189-94.
92. Bismuth C, Gaultier M, Conso F, Efthymiou ML. Hyperkalemia in acute digitalis poisoning: prognostic significance and therapeutic implications. *Clin Toxicol*. 1973;6:153-62.
93. Kelly RA, Smith TW. Recognition and management of digitalis toxicity. *Am J Cardiol*. 1992;69:108G-18G; disc. 18G-19G.
94. Eddleston M, Ariaratnam CA, Sjöström L, et al. Acute yellow oleander (*Thevetia peruviana*) poisoning: cardiac arrhythmias, electrolyte disturbances, and serum cardiac glycoside concentrations on presentation to hospital. *Heart*. 2000;83:301-6.
95. Bandara V, Weinstein SA, White J, Eddleston M. A review of the natural history, toxinology, diagnosis and clinical management of *Nerium oleander* (common oleander) and *Thevetia peruviana* (yellow oleander) poisoning. *Toxicol*. 2010;56:273-81.
96. de Silva HA, Fonseka MM, Pathmeswaran A, et al. Multiple-dose activated charcoal for treatment of yellow oleander poisoning: a single-blind, randomised, placebo-controlled trial. *Lancet*. 2003;361:1935-8.
97. Eddleston M, Juszczak E, Buckley NA, et al. Multiple-dose activated charcoal in acute self-poisoning: a randomised controlled trial. *Lancet*. 2008;371:579-87.
98. Zipes DP, Camm AJ, Borggrefe M, et al. ACC/AHA/ESC 2006 guidelines for management of patients with ventricular arrhythmias and the prevention of sudden cardiac death: a report of the American College of Cardiology/American Heart Association Task Force and the European Society of Cardiology Committee for Practice Guidelines (Writing Committee to Develop Guidelines for Management of Patients With Ventricular Arrhythmias and the Prevention of Sudden Cardiac Death). *J Am Coll Cardiol*. 2006;48:e247-346.
99. Antman EM, Wenger TL, Butler VP, et al. Treatment of 150 cases of life-threatening digitalis intoxication with digoxin-specific Fab antibody fragments. Final report of a multicenter study. *Circulation*. 1990;81:1744-52.
100. Eddleston M, Rajapakse S, Rajakanthan, et al. Anti-digoxin Fab fragments in cardiotoxicity induced by ingestion of yellow oleander: a randomised controlled trial. *Lancet*. 2000;355:967-72.
101. Taboulet P, Baud FJ, Bismuth C, Vicaut E. Acute digitalis intoxication--is pacing still appropriate? *J Toxicol Clin Toxicol*. 1993;31:261-73.
102. Kinlay S, Buckley NA. Magnesium sulfate in the treatment of ventricular arrhythmias due to digoxin toxicity. *J Toxicol Clin Toxicol*. 1995;33:55-9.
103. French JH, Thomas RG, Siskind AP, et al. Magnesium therapy in massive digoxin intoxication. *Ann Emerg Med*. 1984;13:562-6.
104. Castellanos A, Ferreiro J, Pefkaros K, et al. Effects of lignocaine on bidirectional tachycardia and on digitalis-induced atrial tachycardia with block. *Br Heart J*. 1982;48:27-32.
105. Rumack BH, Wolfe RR, Gilfrich H. Phenytoin (diphenylhydantoin) treatment of massive digoxin overdose. *Br Heart J*. 1974;36:405-8.

106. Murray L, Daly F, Little M, Cadogan M. Toxicology Handbook. Marrickville, Australia: Elsevier; 2007.
107. Van Deusen SK, Birkhahn RH, Gaeta TJ. Treatment of hyperkalemia in a patient with unrecognized digitalis toxicity. *J Toxicol Clin Toxicol.* 2003;41:373-6.
108. Erickson CP, Olson KR. Case files of the medical toxicology fellowship of the California poison control system-San Francisco: calcium plus digoxin-more taboo than toxic? *J Med Toxicol.* 2008;4:33-9.
109. Levine M, Nikkanen H, Pallin DJ. The effects of intravenous calcium in patients with digoxin toxicity. *J Emerg Med.* 2011;40:41-6.
110. Gupta A, Su M, Greller H, et al. Digoxin and calcium: the verdict is still out. *J Emerg Med.* 2010;39:102-3.
111. Hansteen V, Jacobsen D, Knudsen K, et al. Acute, massive poisoning with digitoxin: Report of seven cases and discussion of treatment. *Clin Toxicol.* 1981;18:679-92.
112. Carter CL. The constitution of karakin. *J Sci Food Agric.* 1951;2:54-5.
113. Ming L. Moldy sugarcane poisoning--a case report with a brief review. *J Toxicol Clin Toxicol.* 1995;33:363-7.
114. Carter CL, McChesney WJ. Hiptagenic acid identified as beta-nitropropionic acid. *Nature.* 1949;164:575.
115. Skey W. Preliminary notes on the isolation of the bitter substance of the nut of the karaka tree (*Corynocarpus laevigatus*). *Trans Proc R Soc N Z.* 1871;4:316-21.
116. Cambie RC, Ferguson LR. Potential functional foods in the traditional Maori diet. *Mutat Res.* 2003;523-524:109-17.
117. Alexi T, Hughes PE, Faull RL, Williams CE. 3-Nitropropionic acid's lethal triplet: cooperative pathways of neurodegeneration. *Neuroreport.* 1998;9:R57-R64.
118. Ludolph AC, He F, Spencer PS, et al. 3-Nitropropionic acid – Exogenous animal neurotoxin and possible human striatal toxin. *Can J Neurol Sci.* 1991;18:492-8.
119. He F, Zhang S, Qian F, Zhang C. Delayed dystonia with striatal CT lucencies induced by a mycotoxin (3-nitropropionic acid). *Neurology.* 1995;45:2178-83.
120. Anderson R, Majak W, Rasmussen M, et al. Toxicity and metabolism of the conjugates of 3-nitropropanol and 3-nitropropionic acid in forages poisonous to livestock. *J Agric Food Chem.* 2005;53:2344-50.
121. Borlongan CV, Koutouzis TK, Sanberg PR. 3-Nitropropionic acid animal model and Huntington's disease. *Neurosci Biobehav Rev.* 1997;21:289-93.
122. Williams MC, van Kampen KR, Norris FA. Timber milkvetch poisoning in chickens, rabbits, and cattle. *Am J Vet Res.* 1969;30:2185-90.
123. Wright RO, Lewander WJ, Woolf AD. Methemoglobinemia: etiology, pharmacology, and clinical management. *Ann Emerg Med.* 1999;34:646-56.
124. Hammond-Tooke GD, Taylor P, Punchihewa S, Beasley M. *Urtica ferox* neuropathy. *Muscle Nerve.* 2007;35:804-7.
125. Thurston EL, Lersten NR. The morphology and toxicology of plant stinging hairs. *Bot Rev.* 1969;35:393-412.
126. Pilgrim RL. Some properties of the sting of the New-Zealand nettle, *Urtica-ferox*. *Proc R Soc Lond B Biol Sci.* 1959;6:48-56.
127. Kanzaki M, Tsuchihara T, McMorran D, et al. A rat model of *Urtica ferox* neuropathy. *Neurotoxicology.* 2010;31:709-14.
128. Clark FP. Tree nettle (*Urtica-ferox*) poisoning. *N Z Med J.* 1993;106:234.
129. Edwards EK, Edwards EK. Immediate and delayed hypersensitivity to the nettle plant. *Contact Dermatitis.* 1992;27:264-5.
130. Morgan M, Khan DA. Stinging nettle anaphylaxis [abstract]. *J Allergy Clin Immunol.* 2003;111:598.
131. Stoner JG, Rasmussen JE. Plant dermatitis. *J Am Acad Dermatol.* 1983;9:1-15.